

CASE

- **Knee dislocation with soft tissue impingement**



Knee Dislocation with soft tissue impingement

- **History**
- **45 year old male**
- **Motorcycle accident country**
- **Hit tree**
- **Presentation in ER with back pain and painfull swollen knee**

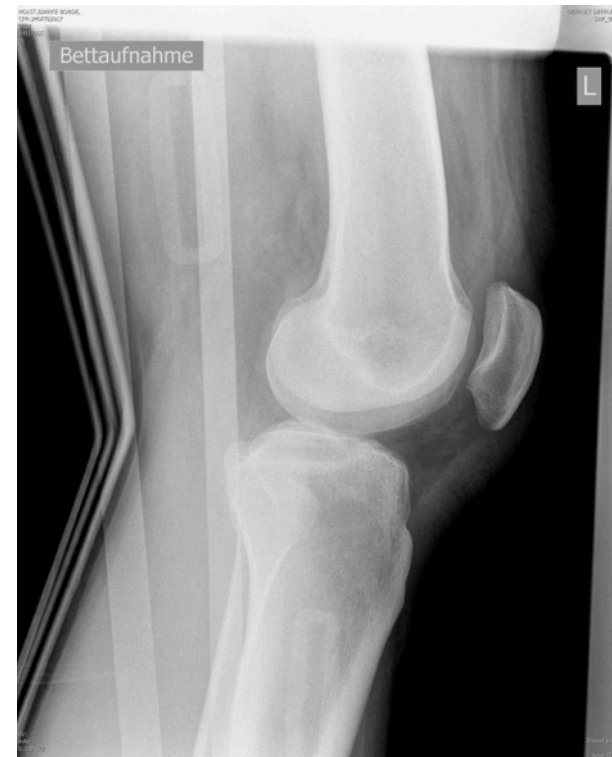
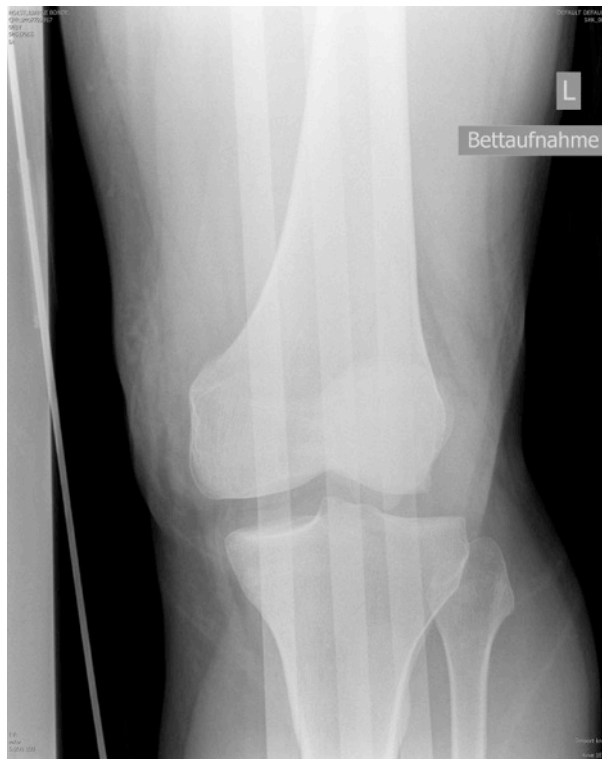
Knee Dislocation with soft tissue impingement

- **At emergency department initial evaluation**
- **Severe medial subluxation**
- **Minor malalignment of knee**
- **Intact neurovascular conditions**

Knee Dislocation with soft tissue impingement

- **X rays**

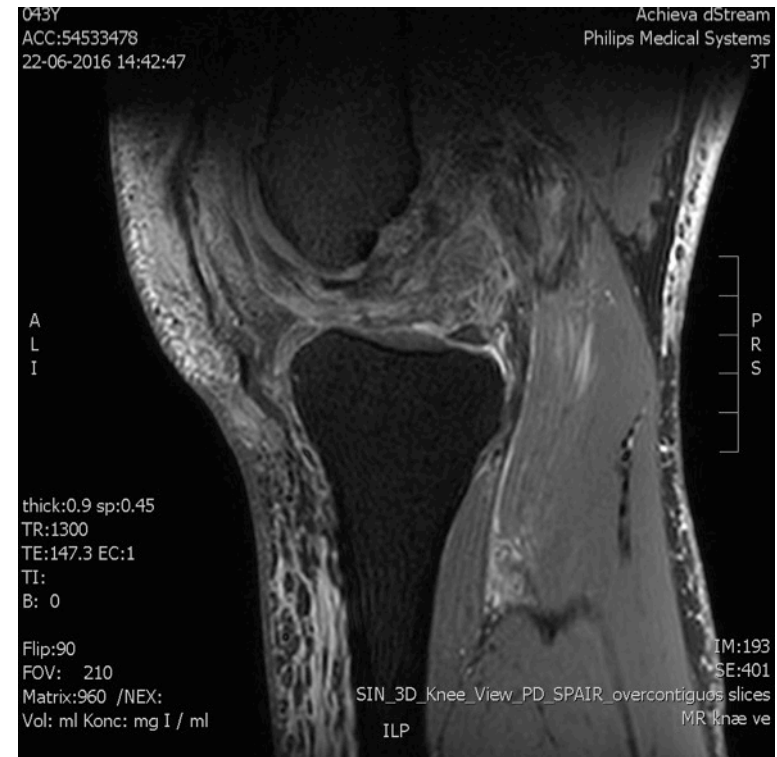
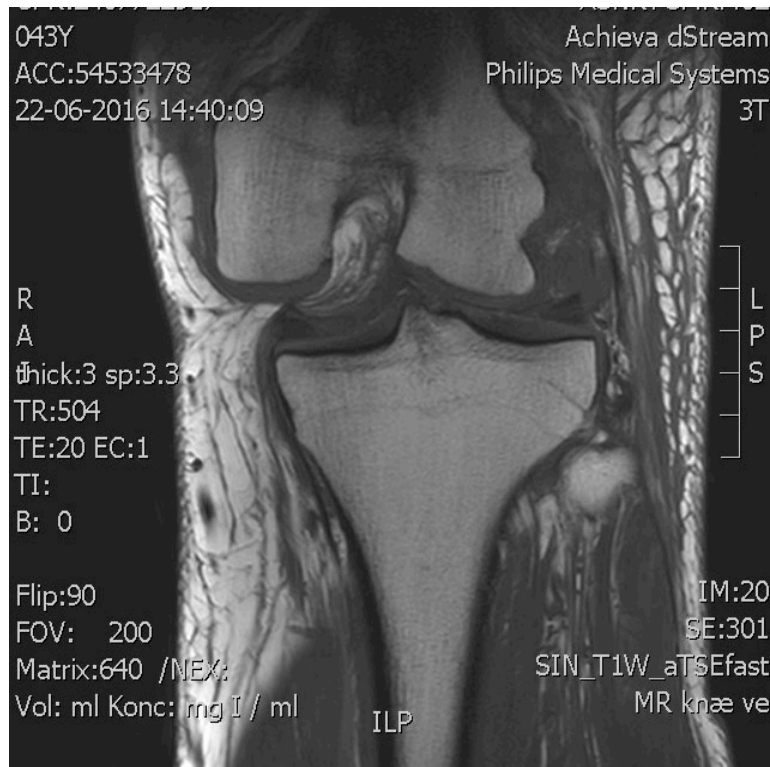
Knee Dislocation with soft tissue impingement

- **Further evaluation ?**

Knee dislocation with soft tissue impingement

- **MRI**



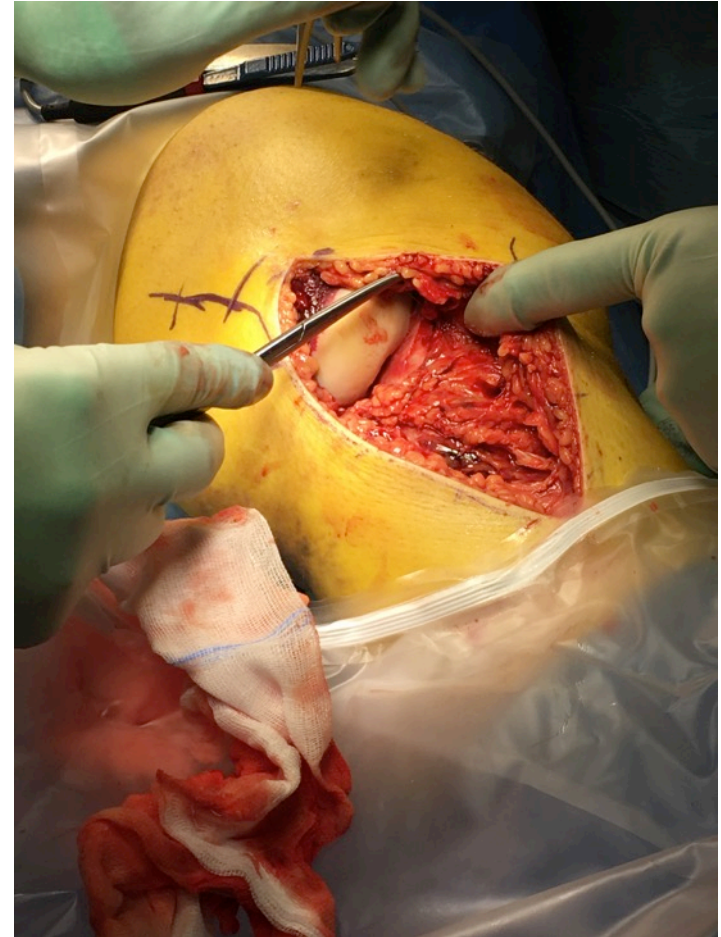
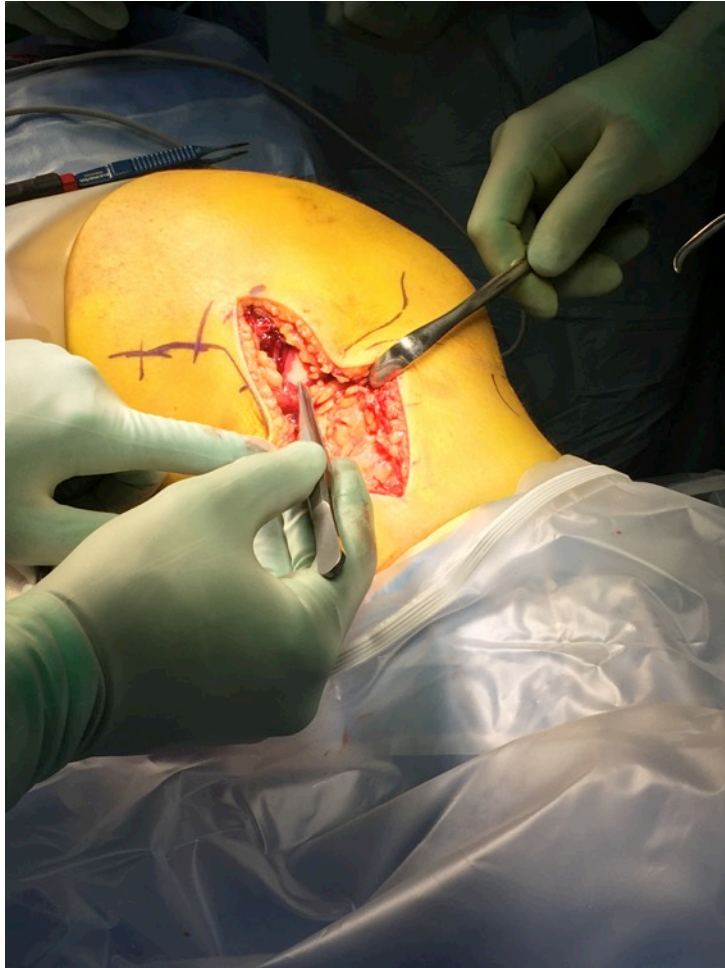Knee Dislocation with soft tissue impingement

- **Treatment ?**

Knee dislocation with soft tissue impingement

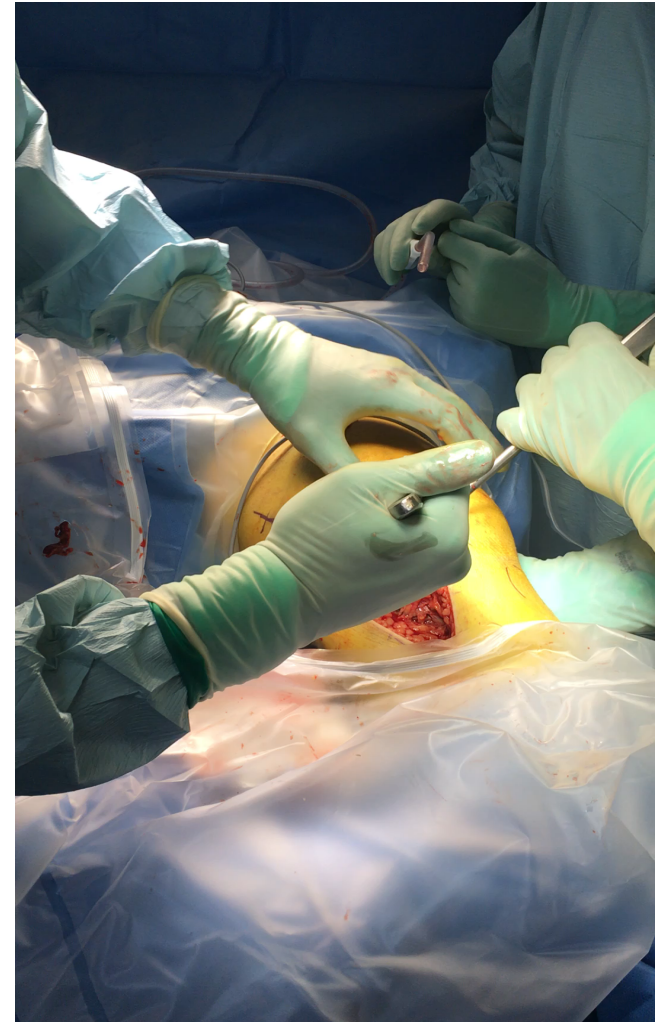
- **Acute surgery**

Knee dislocation with soft tissue impingement



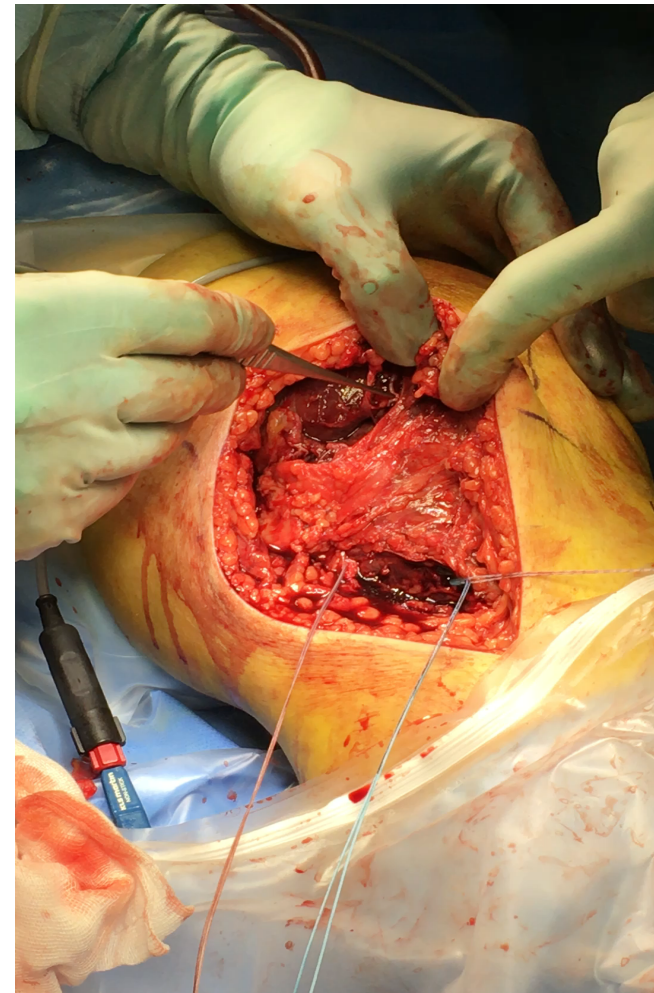
Knee dislocation with soft tissue impingement

- **Acute surgery**
- **Reduce medial**
- **Capsular tissue**



Knee dislocation with soft tissue impingement

- **Acute surgery**
- **MCL repair**



Further surgical plan

- **Brace treatment for PCL/MCL healing**
- **Later ACL/PCL reconstruction**



Evaluation two months after repair procedure and brace treatment

- **Significant**
- **ACL, PCL MCL laxity**

- **PLAN ?**

Final surgery

- **ACL, PCL, MCL**
- **Reconstructions**



One year status

- **ACL stability: good**
- **MCL stability: normal**
- **PCL stability: poor**

- **ROM normal**

- **No ADL pain**

- **Use intermittent brace treatment for some activities til reduce PCL nstability symptom.**

